

CENTENNIAL PARK VETERINARY PRACTICE



A.B.N. 91 072 794 944

VETERINARY EXAMINATION FOR DYNAMIC SYNDICATIONS

At the request of Dynamic Syndications, a pre-sale veterinary examination of **Lot 404, NORTHERN METEOR ex VILLA VALENCIA bay yearling colt**, brands as described in the 2012 Magic Millions Yearling Sale Catalogue, was carried out at the Sales Complex Bundall, Qld, on the 10th January 2012, prior to the commencement of the Magic Millions Yearling Sale.

Clinical Examination:

He was athletic and well balanced with good length of rein. This was is a quality colt. He was well conformed. He is a colt that stands over good ground with an effortless action at the walk. He is a neat, compact, speed style of individual. He presented well for inspection. Both testicles were presented. The colt is still immature and will develop a lot further. All clinical parameters were found to be within normal limits. He was examined in hand, and was found to be free moving. Stethoscope examination of heartbeat was normal. There was no clinical evidence of wear or injury to his extremities. There was no response to flexion tests.

Radiographic Examination:

Pre-sale there was a full set of radiographs available for inspection in the repository at the Magic Millions Sales Complex. Upon examination, there were no radiographic findings of any significance noted.

Endoscopic Examination:

Post sale the upper respiratory tract was examined endoscopically and the larynx and pharynx were found to be normal in appearance and function.

Conclusion:

In my opinion, at the time of this examination, **Lot 404, NORTHERN METEOR ex VILLA VALENCIA bay yearling colt** is in so far as can be determined from the extensive examination conducted; suitable for racing and public syndication and as such, is therefore suitable for all risk mortality insurance cover. I confirm that I advised Dynamic Syndications that in my opinion this lot was suitable for their purchase.

Yours faithfully,



Dr. T.M.B. Roberts BVSc. MRCVS
18 January 2012

NB: This examination is valid for seven (7) days and is only for the use of the person requesting the examination. The issuer of this certificate has no financial interest in the above horse and no contract with any other third party. The issuer has a long standing relationship with Dynamic Syndications to provide a detailed veterinary assessment and specific advice on suitability of prospective yearling purchases at all yearling sales within Australasia.

Veterinary Surgeon: **Dr TMB ROBERTS BVSC. (SYD.) MRCVS**
Telephone: (02) 93606970 Facsimile: (02) 93806203 email: cpvp@bigpond.net.au
PO Box 535 Randwick NSW 2031 AUSTRALIA
www.equinevet.com.au

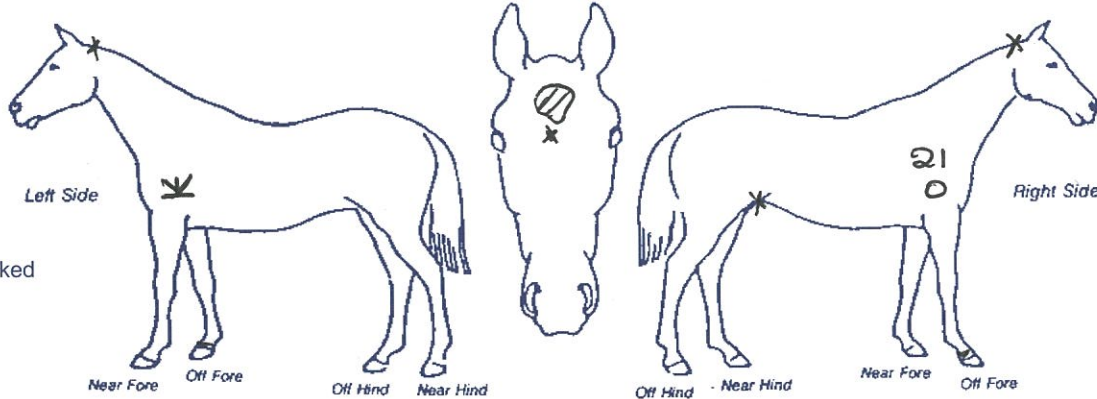
Certificate of Veterinary Examination of a Horse for Insurance



**Cambridge
Equine Hospital**

A division of Cambridge Veterinary Services (1980) Ltd

Horse's Name: UN-NAMED.
 Breed: THOROUGHBRED Sex: COLT Age: 14/10/2010
 Sire: NORTHERN METEOR Dam: VILLA VALENCIA
 Colour: BAY
 Microchip Scanned: Yes No
 Microchip Number: 985100010967727



Whorls marked as X

Markings:

Head: Median whorl eyelevel. Star.

Limbs:

L.F. NK
 R.F. White coronet to pastern behind. White hairs inner & outer knee
 L.H. White both heels.
 R.H. NK.

Body:

Brands: Left shoulder: ∇ Right shoulder/Neck: 21 over O Fire Freeze

Other markings:

This is to certify that at the request of (name and address) D. WATTS, DYNAMIC SYNDICATIONS, AUSTRALIA.

I have examined the horse described above, the property of (name and address) DYNAMIC SYNDICATIONS.

at (place of examination) LYNDHURST FARM, CAMBRIDGE, NEW ZEALAND.

and at the time of examination conducted substantially in accordance with the standard procedure recommended by the New Zealand Equine Veterinary Association, the following signs of disease and/or injury were observed.

Opinion: SUITABLE FOR MORTALITY INSURANCE PURPOSES.

NB. This examination is valid for seven days and is only for the use of the person requesting the examination. The issuer of this certificate has no financial interest in the above horse or no contact with any other third party.


Date 26/11/12. Time Signed 71 Racecourse Road

Veterinary Surgeons

- J J Hope BVSc ■ P A Fraser BVSc ■ M K Brightwell BVSc(dist) ■ I H MacKay BVSc
- L J MacGillivray BVSc ■ A M Hawker BVSc(dist) MACVSc ■ R G Hitchcock BVSc MRCVS
- K R Dingemans BVSc MRCVS
- B Fraser BVSc MSc Cert ES(Orth) Dipl. ECVS MRCVS, Registered Specialist in Equine Surgery
- K Harman BVSc

P O Box 488
 Cambridge 3450
 New Zealand
 Telephone: +64 7 827 7097
 Facsimile: +647 827 0694
 Email: cambridgeeh@xtra.co.nz

26th November 2012



**Cambridge
Equine Hospital**

A division of Cambridge Veterinary Services (1980) Ltd

Mr D. Watts
Dynamic Syndications
Australia

RADIOGRAPHY REPORT

Northern Meteor / Villa Valencia 2010 colt

Lot 387 at the 2012 New Zealand Bloodstock Ready to Run Sales

I have reviewed a 34 view repository series for the above horse taken on 23/10/2012. Slight modelling of the dorso medial aspect of the third metatarsal bone is noted distally. This is not in my opinion of clinical significance. In my opinion there are no significant findings in the above series

A handwritten signature in black ink, appearing to read 'M.K. Brightwell BVSc'. The signature is fluid and cursive, with a large loop at the end.

Dr. M.K. Brightwell BVSc (dist)

Ref: 12-904

IMPORTANT DISCLAIMER

These radiographs were taken as a survey of the most common sites for a lesion. They are not, nor are they meant to be a complete examination of the joints radiographed. They will identify approximately 90% of common lesions. To identify the remaining infrequent lesions or to provide complete coverage of all joints would require many more views. These survey views usually represent the best combination of coverage and economics. It is not a warranty of suitability, soundness or saleability. This report and the findings contained herein are solely for the addressee and may not be used or relied upon by any other person or entity. The interpretation of radiographs and findings may vary with the examiner and a horse's condition hence intending buyers should seek an independent review of the radiographic series from a veterinarian familiar with their particular requirements and expectations.

71 Racecourse Road
PO Box 488
Cambridge 3450
New Zealand

Veterinary Surgeons

J J Hope BVSc P A Fraser BVSc M K Brightwell BVSc(dist) I H MacKay BVSc L J MacGillivray BVSc
A M Hawker BVSc(dist) MACVSc R G Hitchcock BVSc MRCVS K R Dingemans BVSc MRCVS
B Fraser BVSc MSc Cert ES(Orth) Dip. ECVS. Registered Specialist in Equine Surgery S P Christopher BVSc
C P Lawrence BVSc(dist)

Telephone: +64 7 827 7097

Facsimile: +647 827 0694

Email: cambridgeeh@xtra.co.nz